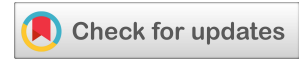

(CASE REPORT)



Brain metastasis from endometrial cancer treated by surgery and stereotaxic radiotherapy on the operating bed: A case report and review of the literature

R. LARAICHI *, K. NOUNI, S. SMITI, O. ALLAOUI, I. SKITIOUI, T. EDITH, A. LACHGAR, H. EL KACEMI, T. KEBDANI and K. HASSOUNI

Department of Radiotherapy, National Institute of Oncology, Mohamed V University, Rabat, Morocco.

World Journal of Biology Pharmacy and Health Sciences, 2024, 20(03), 435-442

Publication history: Received on 13 November 2024; revised on 21 December 2024; accepted on 23 December 2024

Article DOI: <https://doi.org/10.30574/wjbphs.2024.20.3.1060>

Abstract

The occurrence of brain metastases from endometrial cancer is a rare phenomenon. Despite the poor prognosis of this presentation, offering the patient curative ablative treatment, when possible, improves significantly the prognosis and quality of life.

We report in this work the case of a 61-year-old female patient, treated in 2024 for endometrial cancer initially considered to be endometrioid type classified at stage II according to the FIGO 2023 classification, with a grade 3 and presence of vascular emboli. 8 months after her diagnosis, she developed an isolated brain metastasis, without other secondary distant locations. The revelation of this metastasis made it possible to adjust the initial histological diagnosis of endometrial cancer to carcinosarcoma. Our patient was treated by total surgical excision followed by stereotaxic irradiation of the surgical bed at a dose of 27 GY in 3 fractions, with good clinical tolerance. A summary of previous studies and recommendations on the treatment of brain metastases from endometrial cancer was presented.

Keywords: Endometrial cancer; Cerebral metastasis; Stereotaxic radiotherapy; Surgery; Treatment.

1. Introduction

Endometrial cancer ranks fourth among gynecological cancers in Morocco, with an incidence of 3.5 per 100,000 inhabitants. Generally diagnosed at an early stage following postmenopausal metrorrhagia, which must be explored, the prognosis is good with a 5-year survival of 84.5% for all stages and histological types combined. Characterized by a low tropism for the brain, endometrial cancer rarely gives brain metastases (0.3 to 1.4% of cases) [1,2]. We report in this work the case of a patient who presented a single brain metastasis of endometrial cancer, treated first by surgery then by stereotaxic radiotherapy on the cerebral surgical bed at the National Institute of Oncology in Rabat, Morocco.

2. Case presentation

This is a 61-year-old female patient with a history of dysthyroidism under medical treatment for 8 years in good control, menopausal 6 years ago, single and nulliparous, with no case of gynecological cancer described in her family.

The patient presented in January 2024 with moderately abundant postmenopausal metrorrhagia, which prompted her consultation with a gynecologist, who performed a suprapubic pelvic ultrasound showing suspicious endometrial thickening.

* Corresponding author: R. LARAICHI

A pelvic MRI was subsequently performed on January 7, 2024, revealing an endometrial process invading the myometrium by more than 50% and the cervix without pelvic or distant extension classified FIGO II. A thoraco-abdomino-pelvic CT scan performed on January 17, 2024 showed the absence of locoregional or distant extension of the endometrial process already described.

The decision of the treating team was to perform a total hysterectomy with bilateral annexectomy and pelvic dissection; thereby the patient was operated on January 25, 2024. The pathological results subsequently showed that it was a grade 3 endometrioid carcinoma, with positive vascular emboli, the isthmus and cervix were free of tumor infiltration, the pelvic lymph node dissection was however negative, with 8 lymph nodes taken on the right all returning negative and two on the left also negative. The immunohistochemical analysis had shown that P53 was mutated; except that the molecular biology study (NGS: next-generation sequencing: NGS) for molecular stratification of the tumor could not be realized for financial reasons.

The tumor was thus classified as high intermediate risk (according to the recommendations of the ESGO/ESTRO/ESP Guidelines of 2020) since a complete molecular study (POLE E, MSI, P53) could not be carried out, and the decision of the gynaecological multidisciplinary meeting of the national institute of oncology which took place on February 29, 2024 was to perform concomitant radiochemotherapy followed by vaginal barrier brachytherapy and then discuss adjuvant chemotherapy (since the patient has a mutated P53 status but the exact molecular profile has not been determined).

The patient underwent concomitant chemoradiotherapy based on external radiotherapy on the pelvis with the lymph node areas at a dose of 48.6 Gy due to 1,8 Gy per fraction according to the PORTEC 3 protocol with concomitant chemotherapy based on cisplatin 50 mg/m² (D1-D28), followed by vaginal barrier brachytherapy in 2 fractions of 6 Gy, end of treatment on 04/30/2024 with good clinical tolerance of the entire treatment. However, the patient was unable to receive adjuvant chemotherapy due to financial problems following the suspension of her medical coverage and the delay for chemotherapy.

Subsequently, the patient presented in August 2024 with neurological symptoms consisting of headaches with dizziness, complicated by the onset of status epilepticus. The patient was quickly referred to the neurological emergency room where a cerebral MRI angiography was performed on 08/30/2024 revealing: an intra-axial lesion process of the parietal convexity of 30X25mm, accompanied by annular perilesional edema without deviation of the midline, suggesting a secondary lesion to be compared with the histological data (Fig.1).

The patient benefited from excision of the right parietal lesion in neurosurgery (en bloc resection of a cortico subcortical parietal lesion following the peritumoral gliosis) on September 13, 2024

On anatomopathological study: it was a malignant tumor proliferation with a double epithelial and sarcomatous component (carcinosarcoma) whose appearance is in favor of a secondary metastatic origin, the endometrial origin is possible taking into account the patient's history. However, the immunohistochemical data do not support a primitive glial origin.

Subsequently, the patient was referred to us for radiotherapy at the National Institute of Oncology for stereotaxic radiotherapy on the cerebral operative cavity. A postoperative cerebral MRI allowed us to objectify the exact volume of the operative cavity (contouring of the target volume optimized by fusion with MRI) as well as the absence of tumor residue. An extension assessment was also requested based on a pelvic MRI and a thoraco-abdominal CT scan, showing post-radiation vaginal remodeling without any tumor lesion detectable locally (uterine compartment, vagina and pelvis) or remotely.

Our patient received postoperative radiotherapy with curative intent using stereotaxic technique on the operating cavity at a dose of 27 GY in 3 fractions of 9GY, the treatment was spread over one week, and was marked by good clinical tolerance (Fig.2 and 3).

In the post-therapeutic follow-up (one week after the end of irradiation), the patient presented dyspnea with deterioration of the general condition, a thoraco-abdominal CT scan was thus requested urgently, revealing the appearance of secondary pulmonary and hepatic localizations. The patient was therefore referred to medical oncology to start palliative chemotherapy.

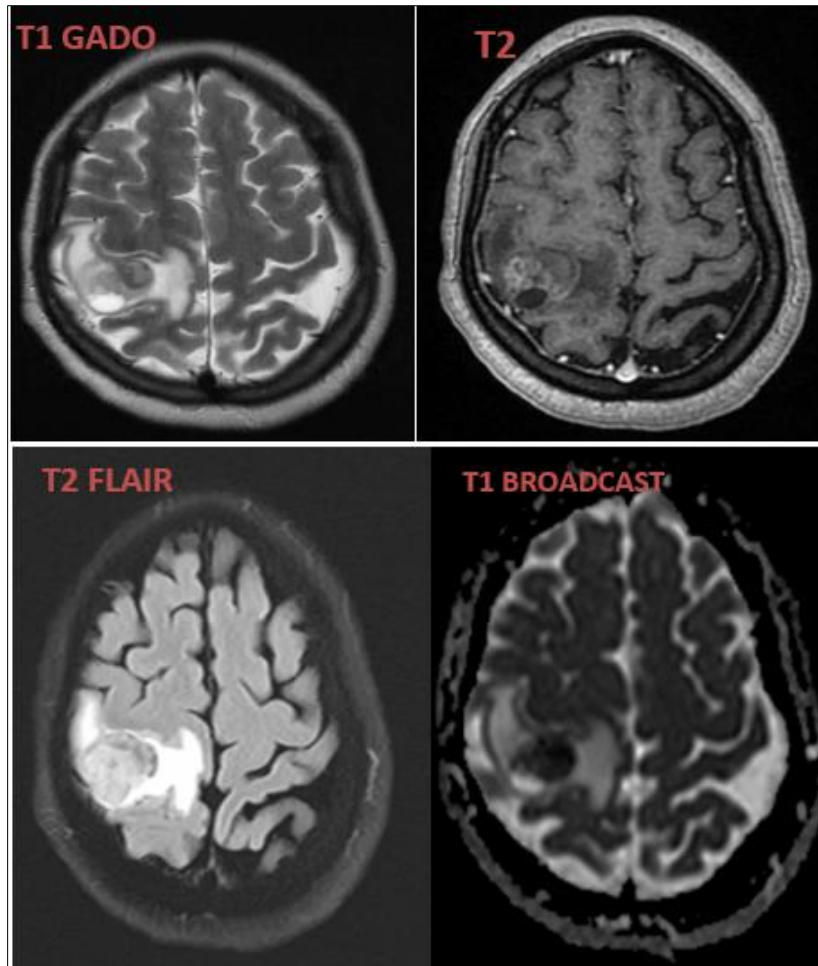


Figure 1 MRI images of an intra-axial lesion process of the right parietal convexity with heterogeneous signal (B), enhanced peripherally after injection (A) associated with annular perilesional edema with focal erasure of cortical sulci (C), absence of diffusion abnormality (D)

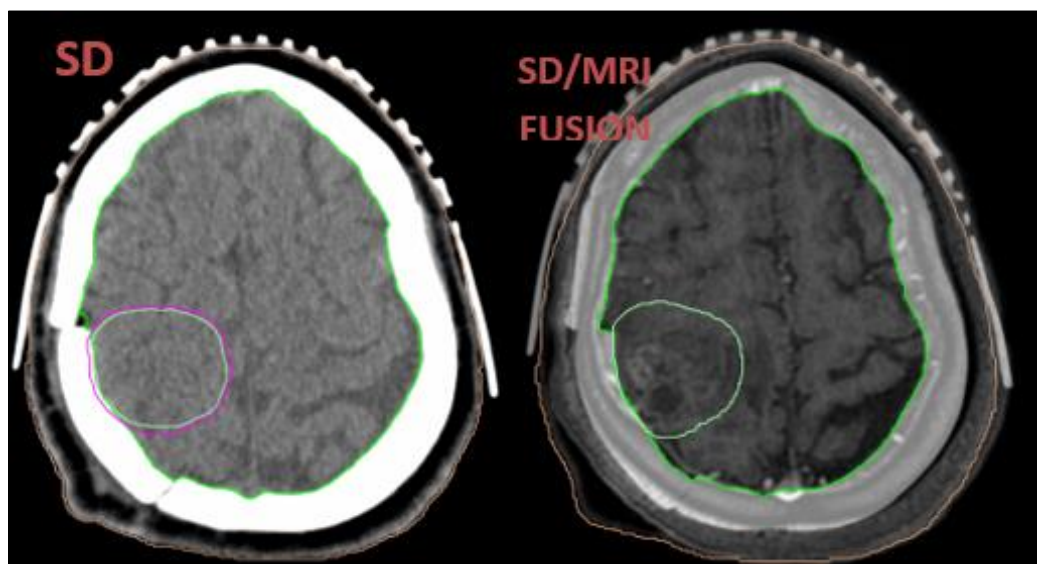


Figure 2 Delineation of the cavity of the resection of the brain metastasis on dosimetric CT scan (A) using fusion with initial brain MRI (B)

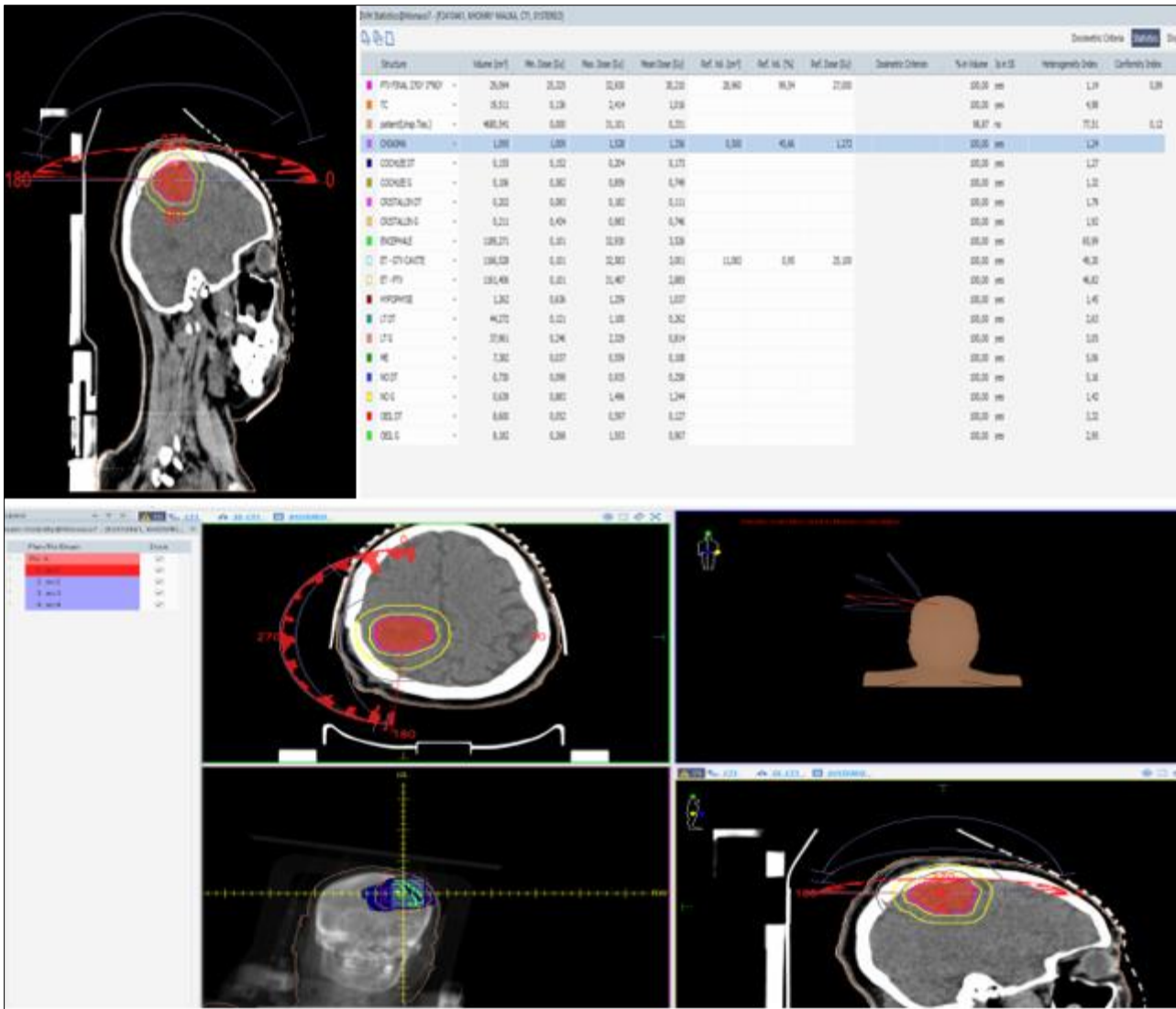


Figure 3 Dosimetric planning and validation of the treatment plan for stereotaxic radiotherapy on the operating bed of a brain metastasis, the prescription was made on the 80% isodose of a total dose of 27 GY (3x9 GY), respecting the dosimetric constraints on the organs at risk.

3. Discussion

Endometrial cancer is ranked among the most common cancers in women worldwide, with an average age at diagnosis of 50 years old. In developed countries, it is often more common due to risk factors such as obesity and an aging population. Risk factors include obesity, diabetes, a history of hormonal dysfunction, and prolonged use of estrogen without progesterone. Its prognosis is quite good, especially in the case of early diagnosis. However, this prognosis becomes worse for non-endometrioid histological type (which is the case of our patient) and in the case of lymph node, peritoneal or distant spread.

During the natural evolution of endometrial cancer, the preferential metastatic sites are located at the pelvic and lymph node (para-aortic) levels [3]. More rarely, metastases are observed at the liver, lung and bone levels. The occurrence of brain metastases from an endometrial primary is, however, a fairly rare phenomenon given the neurophobic nature of this cancer (0.3 to 1.4% of cases), with an approximate incidence of 1.1% in autopsy series [4].

The route of dissemination is hematogenous by the diffusion of cancer cells to the lungs, then to the brain via the pulmonary artery and the carotid arteries [5-6], which explains why patients with brain metastases often have other metastases in extracerebral sites, particularly pulmonary [7]. Despite this, we find in the literature that 49% of patients followed for endometrial cancer have isolated brain metastases, compared to 51% who have brain metastases in the

context of a disseminated disease that also affects extracranial sites, preferentially the pelvis, peritoneum, lung, bones, liver, and lymph nodes [8-10]. It should be noted that in our patient, we diagnosed dissemination of her disease to the pulmonary and hepatic levels after the end of treatment for her brain metastasis.

In a retrospective study, 119 patients with endometrial cancer with brain metastases were included. The age of the patients ranged from 48 to 82 years, with a median of 66 years [8]. The time between diagnosis of the primary tumor and the occurrence of brain metastases was between 0 and 52 months [9-10], with a time of 08 months in our case. At the time of initial diagnosis of endometrial cancer, 36.7% of endometrial tumors were classified as stage I or II, according to the FIGO 2009 classification, while 63.3% were stage III or IV. Regarding tumor grade, 5.5% of patients were grade 1, 16.4% were grade 2, and 78.1% were grade 3. The predominant histological type was endometrioid adenocarcinoma (72.4%), while 27.6% of patients had less favorable histological types, such as adenosquamous carcinoma, clear cell carcinoma, serous carcinoma, or carcinosarcoma [11]. In our case, the patient had endometrial carcinosarcoma, grade 3, stage IIC according to the FIGO 2023 classification.

Few prognostic factors have been identified in the literature as risk factors for disease dissemination and metastases, including brain metastases. These include histological type other than adenocarcinoma, high histological grade, advanced stage of the disease, and the presence of vascular emboli [12,13]. In the case of our patient, three poor prognostic factors were present: aggressive histological type (carcinosarcoma), grade 3 tumor, and the presence of vascular emboli.

Coming to the therapeutic aspect, total brain irradiation remains the reference treatment for multiple brain metastases. On the other hand, for single or few brain metastases, excision surgery or radiosurgery are considered the treatments of choice [14]. Surgery has several advantages, since it can be performed for diagnostic purposes (having histological proof), curative (total resection) or symptomatic (decompression). Surgery is particularly indicated for large tumors (greater than 3 cm in diameter), cystic tumors, very symptomatic lesions and when a histological diagnosis is necessary [15], as was the case of our patient, with an isolated symptomatic tumor of 3 cm and in which the metastatic origin was doubtful. Our patient then underwent surgery by complete excision of the parietal cerebral lesion and an anatomopathological study which confirmed the secondary origin of the resected cerebral process.

However, when surgery is performed exclusively, the risk of local recurrence is approximately 60% [16, 17]. Thus, total brain irradiation as a complement remains recommended [16,18]. Total brain radiotherapy has shown advantages in terms of control of the surgical bed and survival without new metastases with a survival without neurological progression of up to 95%. On the other hand, deterioration in long-term cognitive functions and decrease in quality of life have been demonstrated in patients who have received total brain irradiation [19-22]. Thus, and to limit the acute and late side effects associated with this irradiation [23], some teams have opted for stereotaxic irradiation of the edges of the surgical bed. A meta-analysis of these studies revealed a satisfactory local control rate of approximately 83% [24]. Our patient was able to benefit from stereotaxic radiotherapy on the cerebral operative cavity within 6 weeks of surgery. It should be noted that a median delay of 4 to 6 weeks between surgery for cerebral metastasis and irradiation of the operating beds was most frequently reported in the literature [25].

Regarding the delineation of the surgical cavity, it is necessary to rely on multimodal imaging, integrating data from preoperative and postoperative imaging. In the literature, the anatomoclinical target volume of the surgical bed was generally defined on dosimetric MRI in T1 sequence after injection, taking into account the entire excision cavity, as well as the peripheral contrast uptake at the surgical edges [25]. Thus, the anatomoclinical target volume (CTV) corresponds to the excision cavity, filled with cerebrospinal fluid and delimited by brain tissue considered a priori healthy [25,26]. Cerebral edema is generally not included in this volume [25, 26, 27]. In our case, the delineation of the surgical cavity was based on the fusion of the CT images (dosimetric scanner) and the MRI (pre- and post-operative) of the patient, a margin of 1 mm was added around the anatomical clinical target volume to obtain the predicted target volume (PTV). The choice of this margin was variable in the literature, ranging from 1 mm to 4 mm [25]. Other authors have decided not to put any [28,29].

Regarding the total dose and fractionation schedule used in stereotactic radiotherapy of the surgical bed. ASTRO published recommendations on the dose to be delivered in a single fraction to surgical beds, this dose varied according to the volume of the surgical cavity ranging from 12 GY in a single fraction when the cavity is ≥ 30.0 cm³, up to 20 GY when the cavity volume is < 4.2 cm³ [30]. These recommendations come from a randomized trial comparing postoperative SRS in a single fraction to whole brain radiotherapy (WBRT) (N107C/CEC.3) and are supported by the existing literature [31].

Postoperative stereotactic radiotherapy in multiple fractions (hypofractionated) was also the subject of a randomized study (NCT04114981), in the hope of improving local control and reducing radionecrosis rates compared with single-fraction postoperative radiosurgery. In the study by Soltys and al., the choice of fractionation was determined based on the size of the resection cavity. During treatment in multiple fractions, the median observed volume was 13.8 mL, compared with 6.8 mL in the absence of fractionation [32]. Whereas Prabhu and al. had opted for hypofractionation as soon as the tumor size exceeded 4 cm [33]. In our patient, the radiotherapy staff's decision was to choose a hypofractionated protocol in three fractions of 9 GY allowing the delivery of an effective biological dose of 108 GY (with an Alpha/Beta ratio of the brain = 3), and this based on the volume of the operating cavity which was significant in our case, 30cc.

The prognosis of patients with brain metastases from endometrial cancer is guarded, with a median survival of 1 to 82 months in the literature [34, 35]. However, the presence of a single brain metastasis and the absence of extracerebral dissemination were correlated with a better prognosis at the time of diagnosis of the brain metastasis with a median survival exceeding 4 years [3]. Based on the results of the literature, we believe that our patient benefited from optimal treatment of her brain metastasis.

4. Conclusion

Despite the rarity of brain metastases from endometrial cancer, the appearance of neurological symptoms should prompt any physician to seek this diagnosis even in the absence of local relapse or distant dissemination of the disease. The decision on the optimal treatment should be made in a multidisciplinary consultation meeting in order to offer the patient the optimal management of her pathology. In the case of a single brain metastasis, the reference treatment remains surgery, which will also allow histological confirmation followed by stereotaxic radiotherapy on the operating bed, which has replaced total brain irradiation, thus allowing better local control with less neurocognitive damage. The development of neurosurgical techniques, radiotherapy and systemic treatments has significantly improved the prognosis of these patients.

Compliance with ethical standards

Disclosure of conflict of interest

No conflict of interest to be disclosed.

Statement of informed consent

Informed consent was obtained from all individual participants included in the study.

References

- [1] Aalders JC, Abeler V, Kolstand P. Recurrent adenocarcinoma of the endometrium: A clinical and histopathological study of 379 patients. *Gynecol Oncol.* 1984 Jan;17(1):85-103. PubMed | Google Scholar
- [2] Martinez-Manas RM, Brell M, Rumia J, Ferrer E. Brain metastases in endometrial carcinoma. *Gynecol Oncol.* 1998 Aug;70(2):282-4. PubMed | Google Scholar
- [3] S. Uccella, et al., Primary brain metastases of endometrial cancer: A report of 18 cases and review of the literature, *Gynecol Oncol* (2015),<http://dx.doi.org/10.1016/j.ygyno.2016.04.013>
- [4] E.Henriksen, the lymphatic dissemination in endometrial carcinoma: a study of 188 necropsies. *Am.J.Obstet.Gynecol.*123 (1975 NOV 15) 570-576.
- [5] Gien LT, Kwon JS, D'Souza DP, Radwan JS, Hammond JA, Sugimoto AK, et al. Brain metastases from endometrial carcinoma: a retrospective study. *Gynecol Oncol.* 2004;93(2):524-8 5.
- [6] Katz JM, Segal AZ. Incidence and etiology of cerebrovascular disease in patients with malignancy. *Curr Atheroscler Rep.* 2005;7(4):280-8
- [7] Nasu K, Satoh T, Nishio S, Nagai Y, Ito K, Otsuki T, et al. Clinicopathologic features of brain metastases from gynecologic malignancies: a retrospective study of 139 cases (KCOG-G1001s trial). *Gynecol Oncol.* 2013; 128(2):198-203

- [8] Gien LT, Kwon JS, D'Souza DP et al. Brain metastases from endometrial carcinoma: a retrospective study. *Gynecol Oncol*. 2004 May;93(2):524-8. PubMed | Google Scholar
- [9] Mahmoud-Ahmed AS, Suh JH, Barnett GH, Webster KD, Belinson JL, Kennedy AW. The effect of radiation therapy on brain metastases from endometrial carcinoma: a retrospective study. *Gynecol Oncol*. 2001 Nov;83(2):3059. PubMed | Google Scholar
- [10] Cormio G, Lissoni A, Losa G, Zanetta G, Pellegrino A, and Mangioni C. Brain metastases from endometrial carcinoma. *Gynecol Oncol*. 1996 Apr;61(1):40-3. PubMed | Google Scholar
- [11] Fadila Kouhen et al., Brain metastasis from endometrial cancer: a case report and literature review. *Pan African Medical Journal*. 2015; 20:68 doi:10.11604/pamj.2015.20.68.6097.
- [12] Kottke-Marchant K, Estes ML, Nunez E. Early brain metastases in endometrial carcinoma. *Gynecol Oncol*. 1991 Apr;41(1):6773. PubMed | Google Scholar
- [13] Sewak S, Muggia FM, Zagzag D. Endometrial carcinoma with cerebellar metastasis: a case report and review of the literature. *J Neurooncol*. 2002 Jun;58(2):13740. PubMed | Google Scholar
- [14] Tsao MN, Rades D, Wirth A, Lo SS, Danielson BL, Gaspar LE, et al. Radiotherapeutic and surgical management for newly diagnosed brain metastasis(es): an American Society for Radiation Oncology evidence-based guideline. *Pract Radiat Oncol* 2012;2:210–25, <http://dx.doi.org/10.1016/j.prro.2011.12.004>.
- [15] Yang H, Kano H, Lunsford LD, Niranjan A, Flickinger JC, Kondziolka D. What factors predict the response of larger brain metastases to radiosurgery? *Neurosurgery* 2011;68:682–90, [http://dx.doi.org/10.1227/NEU.0b013e318207a58b\[discussion 690\]](http://dx.doi.org/10.1227/NEU.0b013e318207a58b[discussion 690])
- [16] Kocher M, Soffiatti R, Abacioglu U, Villà S, Fauchon F, Baumert BG, et al. Adjuvant whole-brain radiotherapy versus observation after radiosurgery or surgical resection of one to three cerebral metastases: results of the EORTC 22952–26001 study. *J Clin Oncol* 2011;29:134–41, <http://dx.doi.org/10.1200/JCO.201030.1655>.
- [17] Mahajan A, Ahmed S, Li J, McAleer MF, Weinberg J, Brown PD, et al. Postoperative stereotactic radiosurgery versus observation for completely resected brain metastases: results of a prospective randomized study. *Int J Radiat Oncol Biol Phys* 2016;96:S2, <http://dx.doi.org/10.1016/j.ijrobp.2016.06.022>.
- [18] Patchell RA, Tibbs PA, Regine WF, Dempsey RJ, Mohiuddin M, Kryscio RJ, et al. Postoperative radiotherapy in the treatment of single metastases to the brain: a randomized trial. *JAMA* 1998;280:1485–9
- [19] Chang EL, Wefel JS, Hess KR, Allen PK, Lang FF, Kornguth DG, et al. Neurocognition in patients with brain metastases treated with radiosurgery or radiosurgery plus whole-brain irradiation: a randomized controlled trial. *Lancet Oncol* 2009;10:1037–44, [http://dx.doi.org/10.1016/S1470-2045\(09\)70263-3](http://dx.doi.org/10.1016/S1470-2045(09)70263-3).
- [20] Sun A, Bae K, Gore EM, Movsas B, Wong SJ, Meyers CA, et al. Phase III trial of prophylactic cranial irradiation compared with observation in patients with locally advanced non-small-cell lung cancer: neurocognitive and quality-of-life analysis. *J Clin Oncol* 2011;29:279–86, <http://dx.doi.org/10.1200/JCO.201029.6053>.
- [21] Soffiatti R, Kocher M, Abacioglu UM, Villa S, Fauchon F, Baumert BG, et al. A European Organization for Research and Treatment of Cancer phase III trial of adjuvant whole-brain radiotherapy versus observation in patients with one to three brain metastases from solid tumors after surgical resection or radiosurgery: quality-of-life results. *J Clin Oncol* 2013;31:65–72, <http://dx.doi.org/10.1200/JCO.201141.0639>.
- [22] Brown PD, Jaeckle K, Ballman KV, Farace E, Cerhan JH, Anderson SK, et al. Effect of radiosurgery alone vs. radiosurgery with whole brain radiation therapy on cognitive function in patients with 1 to 3 brain metastases: a randomized clinical trial. *JAMA* 2016;316:401–9, <http://dx.doi.org/10.1001/jama.2016.9839>.
- [23] Ricard D, De Greslan T, Soussain C, Bounolleau P, SallansonnetFroment M, Delmas JM, et al. Neurological complications of brain tumor treatments. *Rev Neurol (Paris)* 2008;164:575–87, <http://dx.doi.org/10.1016/j.neurol.2008.03.014>.
- [24] Gans JH, Raper DM, Shah AH, Bregy A, Heros D, Lally BE, et al. The role of radiosurgery to the tumor bed after resection of brain metastases. *Neurosurgery* 2013;72:317–26, <http://dx.doi.org/10.1227/NEU.0b013e31827.cd60>
- [25] Keller A, et al. Delineation of the surgical bed of operated brain metastases treated by adjuvant stereotaxic irradiation: review of the literature. *Cancer Radiother* (2017), <https://doi.org/10.1016/j.canrad.2017.04.014>

- [26] Do L, Pezner R, Radany E, Liu A, Staud C, Badie B. Resection followed by stereotactic radiosurgery to resection cavity for intracranial metastases. *Int J Radiat Oncol Biol Phys* 2009;73:486–91,<http://dx.doi.org/10.1016/j.ijrobp.2008.04.070>.
- [27] Choi CYH, Chang SD, Gibbs IC, Adler JR, Harsh GR, Lieberson RE, et al. Stereotactic radiosurgery of the postoperative resection cavity for brain metastases: prospective evaluation of target margin on tumor control. *Int J Radiat Oncol Biol Phys* 2012;84:336–42,<http://dx.doi.org/10.1016/j.ijrobp.2011.12.009>
- [28] Johnson MD, Avkshtol V, Baschnagel AM, Meyer K, Ye H, Grills IS, et al. Surgical resection of brain metastases and the risk of leptomeningeal recurrence in patients treated with stereotactic radiosurgery. *Int J Radiat Oncol* 2016;94:537–43,<http://dx.doi.org/10.1016/j.ijrobp.2015.11.022>.
- [29] Kelly PJ, Lin YB, Yu AY, Alexander BM, Hacker F, Marcus KJ, et al. Stereotactic irradiation of the postoperative resection cavity for brain metastasis: a frameless linear accelerator-based case series and review of the technique. *Int J Radiat Oncol* 2012;82:95–101,<http://dx.doi.org/10.1016/j.ijrobp.2010.10.043>.
- [30] V. Gondi et al. Radiation Therapy for Brain Metastases: An ASTRO Clinical Practice Guideline. *Practical Radiation Oncology*: July/August 2022.<https://doi.org/10.1016/j.prro.2022.02.003>
- [31] Brown PD, Ballman KV, Cerhan JH, et al. Postoperative stereotactic radiosurgery compared with whole brain radiotherapy for resected metastatic brain disease (NCCTG N107C/CEC.3): A multicentre, randomized, controlled, phase 3 trial. *Lancet Oncol.* 2017;18:1049-1060.
- [32] Soltys SG, Adler JR, Lipani JD, Jackson PS, Choi CYH, Puataweepong P, et al. Stereotactic radiosurgery of the postoperative resection cavity for brain metastases. *Int J Radiat Oncol* 2008;70:187–93,<http://dx.doi.org/10.1016/j.ijrobp.2007.06.068>
- [33] Prabhu R, Shu HK, Hadjipanayis C, Dhabaan A, Hall W, Raore B, et al. Current dosing paradigm for stereotactic radiosurgery alone after surgical resection of brain metastases needs to be optimized for improved local control. *Int J Radiat Oncol Biol Phys* 2012;83:e61–6,<http://dx.doi.org/10.1016/j.ijrobp.2011.12.017>
- [34] Sawada M, Inagaki M, Ozaki M, Yamasaki M, Nakagawa H, Inoue T, et al. Long-term survival after brain metastases from endometrial carcinoma. *Jpn J Clin Oncol.* 1990 Sep;20(3):3125. PubMed | Google Scholar
- [35] Ogawa K, Yoshii Y, Aoki Y et al. Treatment and prognosis of brain metastases from gynecological cancers. *Neurol Med Chir (Tokyo).* 2008 Feb;48(2):57-62. PubMed | Google Scholar.